

Management of a high-risk pregnancy after cervical amputation. A case report

Abstract

A pregnancy becomes at high-risk when the life of the mother or the fetus is becoming fragile. Nowadays, many health problems come to different women before pregnancy and then extended during and after pregnancy. Health problems can occur before a woman becomes pregnant or during pregnancy. We report the management of a 48-year-old female patient with pregnancy obtained via in vitro fertilization with the use of donor oocytes and prophylactic transabdominal cerclage for history of cervical amputation, diagnosed with gestational diabetes mellitus. During the 38 week of pregnancy she delivered by cesarean section, a healthy fetus.

Keywords: prophylactic transabdominal cerclage, cervical amputation

Introduction

When the fetus or the mother is presented health problems, the pregnancy is considered to be at high-risk^(1,2). The main risk factors include maternal age, in vitro fertilization (IVF), medical conditions before pregnancy like blood pressure raised, lung or kidney disease, autoimmune diseases, all types of cancers or chronic infections untreated. The main medical conditions which occur during pregnancy like preeclampsia, eclampsia, gestational diabetes, multiple births and abnormal placentation⁽²⁾.

The most common form of assisted reproductive technology is IVF which involves extracting eggs, and then transferring of embryos into the uterus⁽³⁾.

Cervical amputation removes ectocervical lesions and most of the endocervical canal and can be performed with a scalpel (i.e. cold knife conization), laser or electrosurgical loop^(4,5). Therapeutic cervical amputation is the preferred modality to treat cervical intraepithelial neoplasia grades 2 and 3⁽⁶⁾.

Case report

We report the case of a 48 year old female gravida 5, para 0 that obtained pregnancy via IVF with the use of donor oocytes. About 11 years prior to this pregnancy she was diagnosed with cervical carcinoma in situ and she underwent cold knife cervical amputation. The patient also had a minor thalassemia.

The patient was diagnosed with inherited thrombophilia, therefore prophylactic doses of low molecular weight heparin were recommended during the pregnancy and puerperium. Rh incompatibility and mild chronic thrombocytosis were also highlighted during the first trimester of pregnancy.

Giving the fact that she had 4 spontaneous abortions and cervical amputation, at 17 weeks of pregnancy a

prophylactic transabdominal cerclage was performed using a 5-mm mersilene band around the internal os of the cervix.

Post-operative she had a favorable evolution using oral tocolitics. At 22 weeks of gestation she was diagnosed with gestational diabetes mellitus (glycated hemoglobin -HbA1 (>6.5%)) for which slow release insulin was indicated (16 UI daily). Preeclampsia was suspected, but this diagnose was infirmed by 24 hours Holter monitorization of the arterial blood pressure.

During the pregnancy the patient was admitted several times in the Department of Obstetrics and Gynecology of University Emergency Hospital in Bucharest for uterine contractions and chronic constipation. The evolution was favorable using the usual tocolitics. She was also advised to eat a high-fiber diet, drink plenty of fluids, especially water and to use glycerin suppositories when needed (Table 1).

During the 38 week of pregnancy she delivered by cesarean section, without any complications, a healthy male fetus of 3300 g boy with APGAR score of 7. The mersilene band used for the prophylactic transabdominal cerclage was removed (Figures 1, 2 and 3). The patient tolerated the cesarean section well, and both infant and mother were discharged 4 days postpartum.

Discussion

A history of cervical amputation is important in order to decide if prophylactic abdominal cerclage is required or not⁽⁷⁾. In our case, because of extremely short cervix, prophylactic transabdominal cerclage was performed. The postoperative evolution was favorable.

Due to the advanced age of patient, IVF was performed using oocytes from a unknown young donor. Also, in our case, cervical amputation could have cause infertility due to cervical abnormalities and stenosis^(4,5).

Delia Grădinaru-Fometescu¹,
Diana Voicu¹,
Octavian Munteanu^{1,2},
Oana Bodean¹,
Sorin Vasilescu¹,
Petre Brătilă²,
Monica Cirstoiu^{1,2}

1. Obstetrics and Gynecology Department, Bucharest Emergency University Hospital, Bucharest, Romania
2. "Carol Davila" University of Medicine and Pharmacy, Bucharest, Romania

Correspondence:
Dr. Octavian Munteanu
e-mail: octav_munteanu@yahoo.com

All authors have participated equally in developing this study.

Received:
June 10, 2017
Revised:
July 11, 2017
Accepted:
August 30, 2017

Table 1 Cervical cerclage - indications⁽¹¹⁾

A history of pregnancy loss in the second trimester (>3 pregnancies) without experiencing painful uterine contractions
History of prophylactic cervical cerclage to previous pregnancies for cervical incompetence
A history of premature birth or spontaneous abortion (before 34 weeks of pregnancy)
Cervical length below 25 mm- measured on ultrasound (before 24 weeks of pregnancy)
Painless cervical dilation- in the second trimester of pregnancy

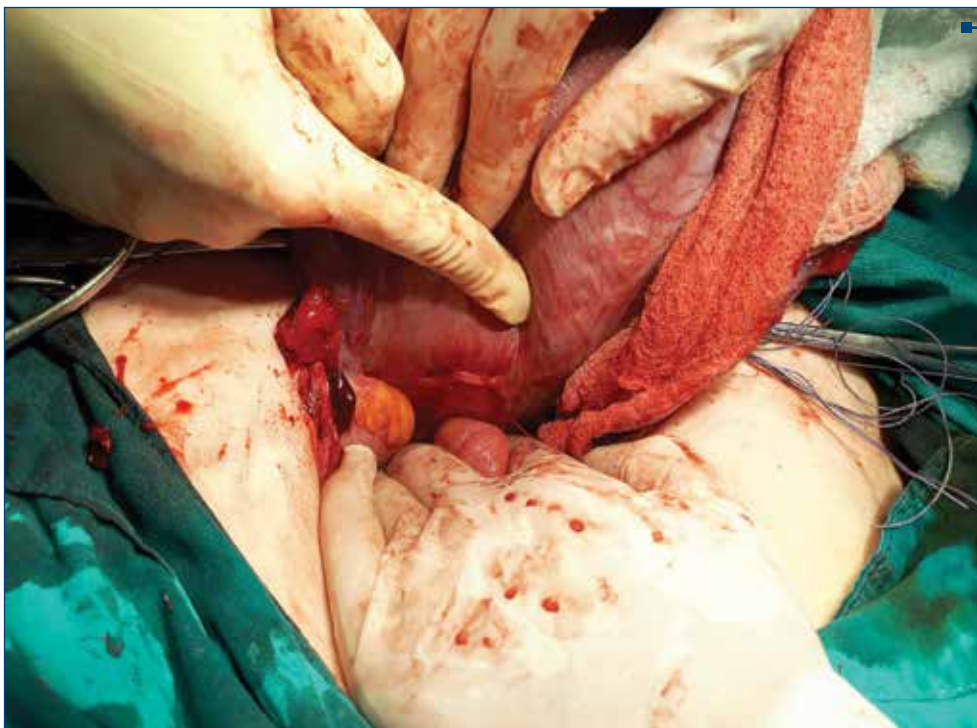

Figure 1. The intraoperative aspect of the band used for the prophylactic transabdominal cerclage (posterior view)

The usual cure for women at risk for cervical disease is a transvaginally cerclage. Mc Donald's procedure is often used, while Shirodka's technique is performed in selected situations⁽⁷⁾.

Cohort studies have shown that both techniques have a 85-90% rate of success⁽⁷⁾. In some cases of severe anatomical defects of the cervix-like our patient or prior transvaginal cerclage failure, transabdominal cerclage becomes the best options⁽⁷⁾.

Benson and Durfee described a procedure which was applied to congenitally short or surgically amputated cervixes⁽⁸⁾.

The placement of an abdominal cerclage may be undertaken by either laparoscopic or open surgical techniques⁽⁹⁾.

A prophylactic abdominal cerclage is recommended at the same time as a trachelectomy: in women of reproductive age who plan to have a child⁽¹⁰⁾. Diagnosis of cervical insufficiency is confirmed by physical examination and ultrasound measurement of the length of the cervix.

Contraindications of cervical cerclage are premature rupture of amniotic membranes, fetal death, severe vaginal bleeding, active labor and chorioamnionitis⁽¹¹⁾.

IVF using oocytes from a young donor was first developed for women with premature ovarian failure or menopause.

The number and quality of a woman's oocytes declines with age. IVF can cause important complications during pregnancy. In some studies, incidence of first

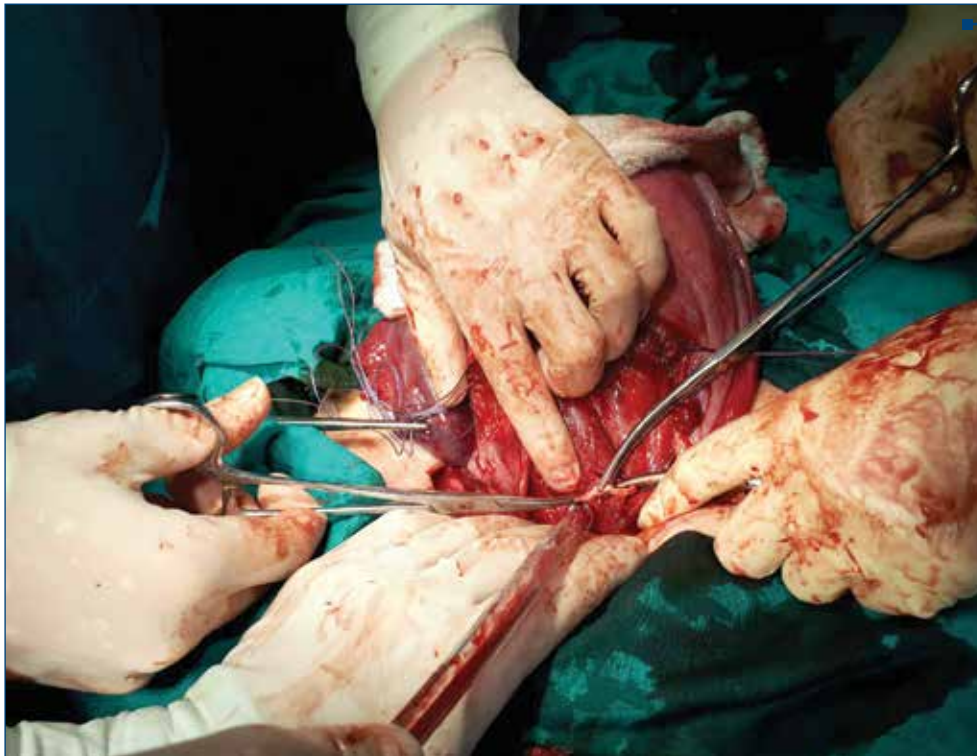

Figure 2. The intraoperative aspect of the band used for the prophylactic transabdominal cerclage (anterior view)

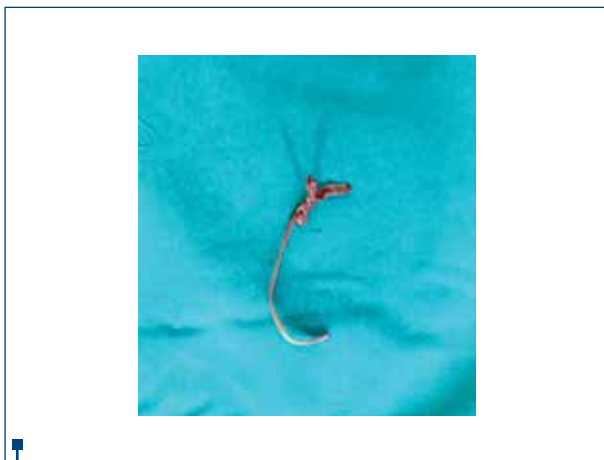


Figure 3. The band used for the prophylactic transabdominal cerclage

trimester venous thromboembolism in relation to IVF was 0.2%⁽¹²⁾. By using ovarian hyperstimulation, about 6-7% of all IVF becomes complicated⁽¹³⁾.

Gestational diabetes is defined as carbohydrate intolerance. The target of insulin therapy especially during pregnancy is to obtain glucose profiles in normal levels⁽¹⁴⁾. As pregnancy advance, the increasing fetal demand for glucose increases the risk of symptomatic hypoglycemia⁽¹⁵⁾.

Conclusions

Maternal age over 45 years, insulin-dependent diabetes mellitus, IVF pregnancy, cervical amputation make this pregnancy to be included in high-risk pregnancies. Patient must receive care from a well-trained team in high risk pregnancies to ensure that mother and baby are better advised during pregnancy. ■

References

1. James DK. et al. High Risk Pregnancy E-Book: Management Options-Expert Consult. Elsevier Health Sciences, 2010.
2. Arias F. et al. (ed.). Practical Guide to High Risk Pregnancy and Delivery-E-Book. Elsevier health sciences, 2012.
3. European IVF-monitoring programme. The Assisted reproductive technology in Europe, 1997. Results generated from European registers by ESHRE. Human Reproduction 2001, 16(2), 384-91.
4. Leiman G, Harrison NA, Rubin A. Pregnancy following conization of the cervix: complications related to cone size. American Journal of Obstetrics and Gynecology 1980, 136(1), 14-8.
5. Morris M. et al. Cervical conization as definitive therapy for early invasive squamous carcinoma of the cervix. Gynecologic Oncology 1993, 51(2), 193-6.
6. Ahlgren M. et al. Conization as treatment of carcinoma in situ of the uterine cervix. Obstetrics & Gynecology 1975, 46(2), 135-40.
7. Cammarano CL, Herron MA, Parer JT. Validity of indications for transabdominal cervicoisthmic cerclage for cervical incompetence. American Journal of Obstetrics and Gynecology 1995, 172(6), 1871-5.
8. Benson RC, Durfee RB. Transabdominal Cervicouterine Cerclage During Pregnancy for the Treatment of Cervical Incompetency. Obstetrics & Gynecology 1965, 25(2), 145-55.
9. Bratila E, Bratila CP, Coroleuca C. Abdominal cerclage during pregnancy. Balkan Medical Union 2015, 50(1), 121-3.
10. Shepherd JH, Milliken DA. Conservative surgery for carcinoma of the cervix. Clinical Oncology 2008, 20(6), 395-400.
11. American College of Obstetricians and Gynecologists. et al. ACOG Practice Bulletin No. 142: Cerclage for the management of cervical insufficiency. Obstetrics and Gynecology 2014, 123(2), Pt 1, 372.
12. Rova K, Passmark H, Lindqvist PG. Venous thromboembolism in relation to in vitro fertilization: an approach to determining the incidence and increase in risk in successful cycles. Fertility and Sterility 2012, 97(1), 95-100.
13. Picaud JC. et al. Neonatal mortality and morbidity in preterm infants born from assisted reproductive technologies. Acta Paediatrica 2012, 101(8), 846-51.
14. Stuebe AM. et al. Gestational glucose tolerance and maternal metabolic profile at 3 years postpartum. Obstetrics and Gynecology 2011, 118(5), 1065.
15. Becerra JE. et al. Diabetes mellitus during pregnancy and the risks for specific birth defects: a population-based case-control study. Pediatrics 1990, 85(1), 1-9.